

Point of Care Echocardiogram

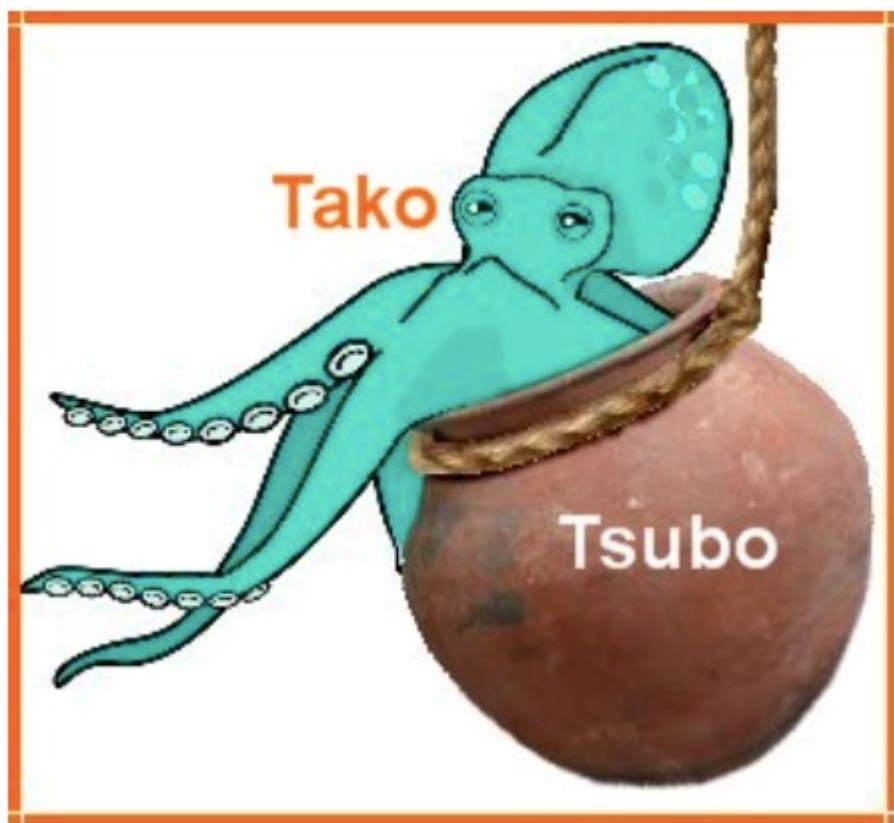
Takotsubo cardiomyopathy, apical ballooning syndrome, or broken heart syndrome



Medical Director of Critical Care Services
Sanford Health System
Associate Professor, University of North Dakota

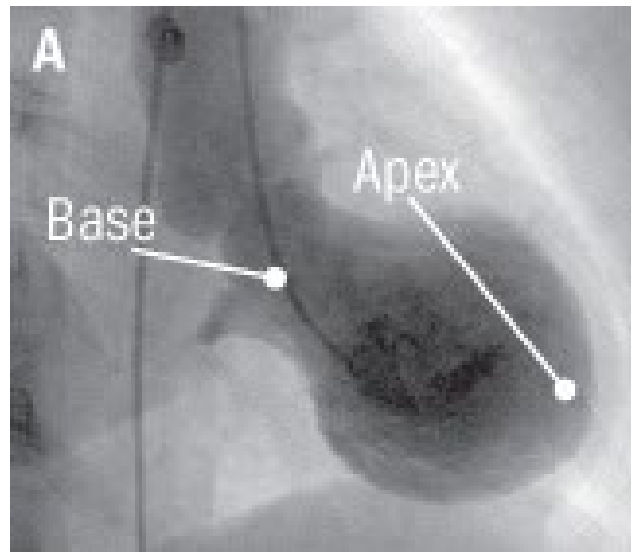
What is “Tako-tsubo”?

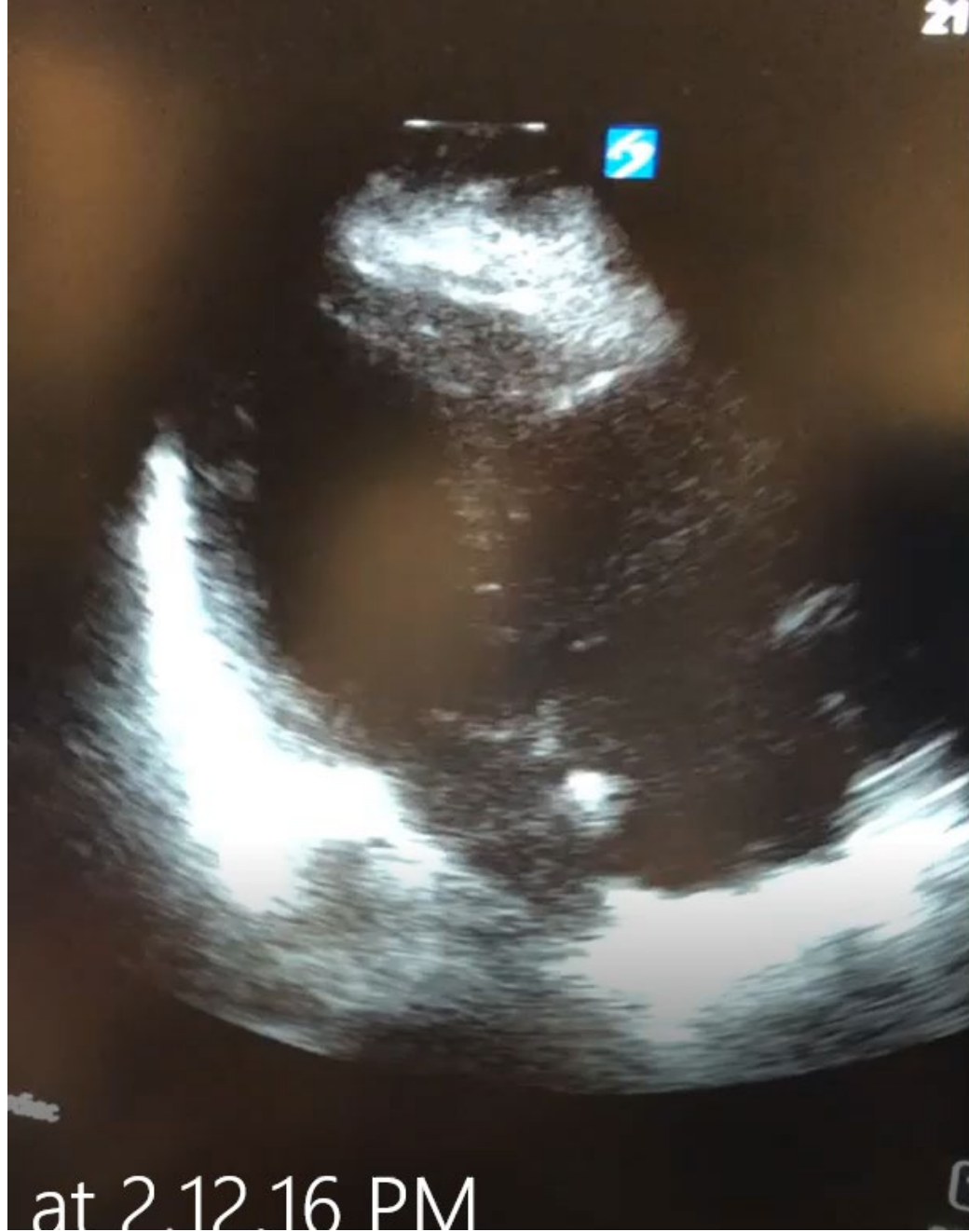
A round-bottomed, narrow-necked vessel used to catch octopuses

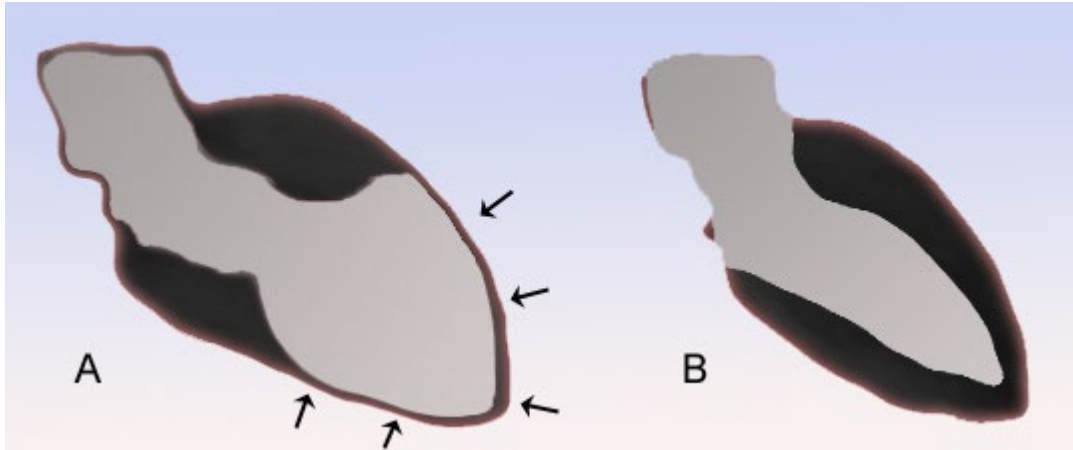


Takotsubo Cardiomyopathy

Reversible left ventricular apical and mid-wall motion abnormalities seen on echocardiography that do not follow the anatomical distribution of normal blood supply of the ventricle. It has a characteristic transient “ballooning” of the left ventricular apex. However, affected patients have no evidence of coronary artery disease on catheterization. Left ventricular function can be severely impaired but typically returns to normal within days to weeks.







Thank You
